

Anesthetic care of a patient with succinic semi-aldehyde dehydrogenase deficiency

J. Flowers¹, G. Veneziano^{1,2}, G. Cambier^{1,2}, J. D. Tobias^{1,2}

¹Department of Anesthesiology and Pain Medicine, The Ohio State University College of Medicine, Columbus, Ohio, USA

²Department of Anesthesiology and Pain Medicine, Nationwide Children's Hospital, Columbus, Ohio, USA

Corresponding author: J. D. Tobias Department of Anesthesiology and Pain Medicine, Nationwide Children's Hospital, Columbus, Ohio, USA. Email: Joseph.Tobias@Nationwidechildrens.org

Keypoints

1. Succinic semialdehyde dehydrogenase (SSADH) deficiency is a rare autosomal recessive disorder with an incidence of approximately 1:500,000 that affects the degradation of gamma-aminobutyric acid (GABA) within the central nervous system.
2. Presenting sign and symptoms include hypotonia, developmental delay, cognitive impairment, expressive language deficits, and ataxia. Seizures remain a hallmark of the disorder, being present in approximately half of affected individuals.
3. Medical treatment is aimed toward symptomatic treatment including control of central nervous involvement including seizures and behavioral concerns such as aggression. Continuing anti-epileptic agents perioperatively is suggested to decrease risk of perioperative seizures.
4. Anesthetic considerations for SSADH deficiency that may impact anesthetic management include the associated seizure disorder, hypotonia, and behavioral issues.

Abstract

Succinic semialdehyde dehydrogenase (SSADH) deficiency is an uncommon autosomal recessive disorder that affects the degradation of gamma-aminobutyric acid (GABA) within the central nervous system (CNS). Clinical manifestations generally present during infancy including hypotonia, developmental delay, cognitive impairment, expressive language deficits, and ataxia. Seizures are a hallmark of the disorder, being present in approximately half of affected individuals. Given the multi-system involvement of these patients with a high incidence of associated seizures, anesthetic care may be required for diagnostic imaging or therapeutic interventions. We present a 23-year-old woman with SSADH deficiency who required anesthetic care during dental surgery. The basic pathophysiology and inheritance of

SSADH is presented, clinical manifestations and end-organ involvement reviewed, and potential anesthetic implications outlined.

Keywords

Succinic semialdehyde dehydrogenase deficiency; gamma-aminobutyric acid; pediatric anesthesiology; seizures

Introduction

Succinic semialdehyde dehydrogenase (SSADH) deficiency is a rare autosomal recessive disorder that affects the degradation of gamma-aminobutyric acid (GABA), an inhibitory neurotransmitter of the brain.¹ The disorder results from the deficiency of the enzyme, SSADH due to mutations in the gene ALDH5A1, which has been

mapped to the short arm of chromosome 6 (6p22.3).² During catabolism, GABA is first converted to succinate semialdehyde (SSA) by GABA-transaminase followed by the conversion of SSA to succinic acid. The process is modulated by the enzyme, SSADH. In the absence of SSADH, GABA is converted to 4-hydroxybutyrate (GHB), resulting in 4-hydroxybutyrate aciduria and excessive GHB concentrations in peripheral tissues, body fluids, and the CNS.³⁻⁵ The high concentration of GHB has been postulated to result in a down-regulation of GABA_B receptors and a high incidence of seizures and other CNS signs and symptoms including progressive encephalopathy and mental retardation.^{6,7}

SSADH was first described by Dr. Cornelius Jakobs in 1981 in a 20-month-old infant who presented with developmental delay, seizures, and associated neurologic involvement.³ To date, only 450-500 patients have been cited in the literature as having been diagnosed with the disorder. Given the multi-system involvement of these patients with a high incidence of associated seizures, anesthetic care may be required for diagnostic imaging or therapeutic interventions. We present a 23-year-old woman with SSADH deficiency who required anesthetic care during dental surgery. The basic pathophysiology and inheritance of SSADH is presented, clinical manifestations and end-organ involvement reviewed, and potential anesthetic implications outlined.

Case report

Review of this case and presentation in this format followed the guidelines of the Institutional Review Board at Nationwide Children's Hospital (Columbus, Ohio). The patient was a 23-year-old, 82.1 kilogram woman who presented for dental extractions and repair. Comorbid conditions included SSADH deficiency diagnosed during infancy due to the onset of seizures and development delay. Comorbid conditions included obesity (BMI 31 kg/M²), seizures, attention deficit hyperactivity disorder, and enuresis. Current medications included

levetiracetam (1000 mg BID) and demethylphenidate (10 mg once a day). There were no allergies and only one previous anesthetic encounter for sedation during magnetic resonance imaging (MRI). There was a history of postoperative nausea and vomiting (PONV) following anesthesia for the MRI. The patient was held *nil per os* for 8 hours except for her usual morning dose of levetiracetam. Premedication for PONV prophylaxis included placement of a scopolamine patch and oral aprepitant (40 mg). The patient was transported to the operating room where standard American Society of Anesthesiologists monitors were placed. Following the inhalation of 50% nitrous in oxygen, a peripheral intravenous cannula was placed. Anesthesia was induced with midazolam (2 mg), propofol (200 mg), and fentanyl (100 µg). Neuromuscular blockade was provided by succinylcholine (100 mg). Following topical preparation of the nasopharynx with 0.5% oxymetazoline, direct laryngoscopy was performed with a #3 MacIntosh laryngoscope and a 6.0 mm cuffed nasotracheal tube was placed. Maintenance anesthesia included sevoflurane (expired concentration 1-1.5%) in 50% nitrous oxide and oxygen. The surgical procedure lasted approximately 1 hour 45 minutes. Additional intraoperative medications included dexamethasone (8 mg) and ketorolac (30 mg). Total intraoperative fluids included 600 mL of lactated Ringers. Following the procedure, the patient's trachea was extubated and she was transported to the post-anesthesia care unit. The postoperative course was unremarkable and the patient was discharged home.

Discussion

SSADH deficiency is a rare autosomal recessive with a reported incidence of approximately 1:500,000. The deficiency of SSADH affects the degradation of GABA (Figure 1). Although clinical manifestations are highly variable and nonspecific which may delay the diagnosis, the onset of clinical signs and symptoms generally begin during the first 6-12 months of life. Presenting sign and symptoms include hypotonia, developmental delay,

cognitive impairment, expressive language deficits, and ataxia.⁶⁻⁸ Seizures remain a hallmark and prominent finding of the disorder, being present in approximately half of affected individuals. Hyperactive behavior, aggressive disorders, self-injurious behavior, hallucinations, and sleep disturbances are also common. Basal ganglia involvement manifested by movement disorders including choreoathetosis, dystonia, and myoclonus has been reported in a few individuals with earlier-onset, more severe disease. Involvement outside of the CNS has not been described.

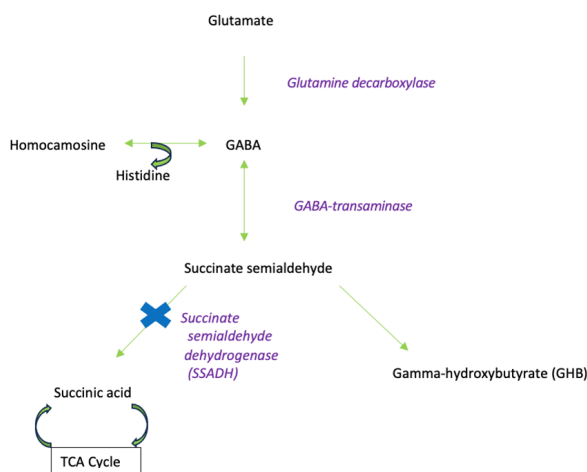


Figure 1. Metabolism of glutamate and γ -amino butyric acid (GABA) including the impact of succinate semialdehyde dehydrogenase (SSADH) deficiency. TCA = tricarboxylic acid or Krebs cycle.

Although the diagnosis may be suggested by the clinical presentation, laboratory confirmation includes urine and plasma organic acid analysis demonstrating elevated 4-hydroxybutyric aciduria. However, current routine newborn screening tests that include identification of numerous disorders of organic acid metabolism do not identify SSADH deficiency. MR imaging generally reveals T2-weighted hyperintense signals in the globus pallidum, cerebellar dentate nuclei, subthalamic nuclei, subcortical white matter, and brain stem. EEG findings are non-specific including generalized background slowing and generalized spike discharges. The diagnosis is confirmed by the identification of biallelic pathogenic variants in the enzyme, ALDH5A1.

Treatment is symptomatic and aimed at controlling the primary neurologic manifestations of the disorder.

Commonly prescribed anti-convulsant medications include lamotrigine, levetiracetam, and topiramate. Valproate is contraindicated in this patient population due to its potential to inhibit any remaining function of the SSADH enzyme.⁸ Behavioral disturbances including ADHD, OCD, and aggression are common in SSADH deficiency. Stimulant medications including methylphenidate are frequently prescribed to control ADHD while selective serotonin reuptake inhibitors may be effective for control of aggressive behavior, anxiety, and OCD. Antipsychotic medications including thioridazine and risperidone may be required for severe anti-social and aggressive behavioral manifestations.

As with all anesthetic care, the perioperative care of patients with SSADH deficiency begins with a thorough preoperative examination and identification of end-organ involvement. CNS involvement is common in these patients including seizures, developmental delay, and behavioral disorders. The current anticonvulsant regimen should be identified and the magnitude and type of seizures documented. Measures to limit the potential for perioperative exacerbation of an underlying seizure disorder include assurance of therapeutic anticonvulsant levels prior to the surgical procedure with optimization of therapy as needed by the pediatric neurology service. Routine anticonvulsant medications should be administered the day of surgery to ensure that routine doses are not omitted.⁹ Administration is suggested even in the setting of routine perioperative *nil per os* status. For prolonged procedures, redosing of anticonvulsant medications may be necessary intraoperatively to maintain therapeutic levels during prolonged surgical procedures. When enteral administration is not feasible, either preoperatively or postoperatively, alternative routes of delivery including intravenous administration or transitioning to alternative agents should be considered. Consultation with the neurology or pharmacology service is suggested when questions arise concerning dosing conversion from enteral to intravenous administration.¹⁰

In general, the choice of anesthetic agents may have limited impact on the perioperative care of patients with seizure disorders.¹¹ The inhalational and intravenous anesthetic agents including the barbiturates, propofol, and benzodiazepines have potent anticonvulsant properties. These agents have been used successfully to treat status epilepticus that is refractory to conventional therapy.^{12,13} Seizure-like motor activity and occasional spike and wave activity on the EEG may be seen with the administration of sevoflurane. These effects are uncommon and generally occur only with high inspired concentrations used for anesthetic induction. As such, the use of sevoflurane is acceptable even in a patient with an underlying seizure disorders.¹⁴

Although not prominent in our patient, hypotonia and progressive neurologic impairment may be present in these patients. Given the associated involvement of the CNS and the limited evidence-based medicine regarding anesthetic care of these patients, no definitive recommendations can be made regarding the choice and safety of specific neuromuscular blocking agents (NMBAs). Given the lack of significant hypotonia and peripheral nervous involvement in our patient, succinylcholine was used to facilitate endotracheal intubation. With potential for adverse effects including rhabdomyolysis and hyperkalemia, succinylcholine is relatively contraindicated in patients with clinically significant hypotonia or peripheral nervous system involvement.^{15,16} Although ongoing neuromuscular blockade was not required in our patient, specific concerns may exist with the use of such agents in patients with CNS disorders with hypotonia including an exaggerated and prolonged response to non-depolarizing NMBAs including rocuronium, vecuronium, and even cis-atracurium. Dosing based on monitoring the train-of-four may be helpful to guide redosing, document reversal, and avoid prolonged recovery times. Residual neuromuscular blockade should be reversed at the completion of the procedure and full recovery documented prior to tracheal extubation. In patients with hypotonia, reversal of steroidal NMBAs (vecuronium or *Flowers et al. Succinic semi-aldehyde dehydrogenase deficiency*

rocuronium) with sugammadex may be preferable given its limited adverse effect profile and superior efficacy when compared to cholinesterase inhibitors.¹⁷

Significant CNS involvement with hypotonia and poor upper airway tone or control may predispose these patients to develop upper airway obstruction or respiratory failure in postoperative period. These issues may be potentiated by the residual effects of anesthetic agents. Whenever feasible, short acting agents whose effects dissipate rapidly should be considered. Postoperative monitoring of respiratory function may be indicated in selected patients based on the patient's status, the surgical procedure, and the choice of anesthetic agents.

Home medications including serotonin reuptake inhibitors (SSRI) or antipsychotic agents, which are prescribed to control aggressive or anti-social behavior, should be continued perioperatively. Premedication with intranasal medications (dexmedetomidine or midazolam) or intramuscular ketamine may be required based on the patient's cognitive status and ability to cooperative with care.¹⁸ In patients chronically receiving SSRIs, potentiation of serotonergic pathways and develop of serotonin syndrome may occur as perioperative medications including ondansetron, fentanyl, oxycodone, and meperidine can potentiate serotonin pathways.¹⁹

In summary, SSADH deficiency is a rare autosomal-recessive inborn error of metabolism associated with a defect in the metabolism of GABA. The majority of SSADH patients will have a similar constellation of CNS symptoms including hypotonia, developmental delay, cognitive impairment, seizures, and ataxia. Anesthetic considerations for these patients include continuing home anti-seizure medications, continuing home behavioral medications, and using short-acting anesthetic and neuromuscular blocking agents to decrease the risk of residual blockade and the potential for respiratory insufficiency.

References

1. Malaspina P, Rouillet JB, Pearl PL, Ainslie GR, Vogel KR, Gibson KM. Succinic semialdehyde dehydrogenase deficiency (SSADHD): Pathophysiological complexity and multifactorial trait associations in a rare monogenic disorder of GABA metabolism. *Neurochem Int.* 2016;99:72-84.
2. Didiášová M, Banning A, Brennenstuhl H, Jung-Klawitter S, Cinquemani C, Opladen T, Tikkanen R. Succinic semialdehyde dehydrogenase deficiency: An update. *Cells.* 2020;9(2):477.
3. Jakobs C, Bojasch M, Mönch E, Rating D, Siemes H, Hanefeld F. Urinary excretion of gamma-hydroxybutyric acid in a patient with neurological abnormalities. The probability of a new inborn error of metabolism. *Clin Chim Acta.* 1981;111(2-3):169-78.
4. Busardò FP, Jones AW. GHB pharmacology and toxicology: acute intoxication, concentrations in blood and urine in forensic cases and treatment of the withdrawal syndrome. *Curr Neuropharmacol.* 2015;13(1):47-70.
5. Gibson KM, Sweetman L, Nyhan WL, Jakobs C, Rating D, Siemes H, Hanefeld F. Succinic semialdehyde dehydrogenase deficiency: An inborn error of gamma-aminobutyric acid metabolism. *Clin Chim Acta.* 1983;133:33-42.
6. Pearl PL, Novotny EJ, Acosta MT, Jakobs C, Gibson KM. Succinic semialdehyde dehydrogenase deficiency in children and adults. *Ann Neurol.* 2003;54(Suppl. 6):S73-S80.
7. Pearl PL, Shukla L, Theodore WH, Jakobs C, Michael Gibson K. Epilepsy in succinic semialdehyde dehydrogenase deficiency, a disorder of GABA metabolism. *Brain Develop.* 2011;33(9):796-805.
8. Pearl PL, DiBacco ML, Papadelis C, Opladen T, Hanson E, Rouillet JB, Gibson KM. Succinic semialdehyde dehydrogenase deficiency: review of the natural history study. *J Child Neurol.* 2021; 36:1153-61.
9. Jones CT, Raman VT, DeVries S, Cole JW, Kelleher KJ, Tobias JD. Optimizing anticonvulsant administration for children before anesthesia: a quality improvement project. *Pediatr Neurol.* 2014;51(5):632-40.
10. Anderson GD, Saneto RP. Current oral and non-oral routes of antiepileptic drug delivery. *Adv Drug Deliv Rev.* 2012;64:911-8.
11. Perks A, Cheema S, Mohanraj R. Anaesthesia and epilepsy. *Br J Anaesth.* 2012;108(4):562-71.
12. Mastrangelo M, Celato A. Diagnostic work-up and therapeutic options in management of pediatric status epilepticus. *World J Pediatr.* 2012;8:109-15.
13. Tobias JD. Therapeutic applications and uses of inhalational anesthesia in the pediatric intensive care unit. *Pediatr Crit Care Med.* 2008;9:169-79.
14. Kofke WA. Anesthetic management of the patient with epilepsy or prior seizures. *Curr Opin Anaesthesiol.* 2010;23:391-9.
15. Katz JA, Murphy GS. Anesthetic consideration for neuromuscular diseases. *Curr Opin Anaesthesiol.* 2017;30(3):435-40.
16. Martyn JA, Richtsfeld M. Succinylcholine-induced hyperkalemia in acquired pathologic states: etiologic factors and molecular mechanisms. *Anesthesiology.* 2006;104:158-69.
17. Tobias JD. Current evidence for the use of sugammadex in children. *Pediatr Anesth.* 2017;27:118-25.
18. Heikal S, Stuart G. Anxiolytic premedication for children. *BJA Education.* 2020;20(7):220-225.
19. Bartakke A, Corredor C, van Rensburg A. Serotonin syndrome in the perioperative period. *BJA Education.* 2020;20(1):10-17.